

Figs. 77, 78. *Oradarea longimana*, n. g. & n. sp. 79. Third segment of metasome. 80. Upper antenna. 81. Mandible. 82. Posterior lip. 83. First maxilla. 84. Second maxilla. 85. Maxillipedes. 86. First gnathopod. 87. Second gnathopod. 88. Fifth peræopod. 89. Third uropods and telson.

PLATE 11.

Fig. 90. *Atyloides serraticauda*, Stebbing. Third segment of metasome.
 Fig. 91. *Atylus antarcticus*, n. sp. 92. Upper antenna. 93. First gnathopod. 94. First peræopod. 95. Upper part of 3rd peræopod. 96. Upper part of 5th peræopod. 97. Third uropods and telson.
 Fig. 98. *Jassa goniamera*, n. sp. 99. Upper antenna. 100. Maxillipedes. 101. First gnathopod. 102. Second gnathopod. 103. First peræopod. 104. Third peræopod. 105. Fifth peræopod. 106. Second and third uropods and telson. 106 a. Extremity of 3rd uropods.

On the Anatomy of the Pig-footed Bandicoot (*Chæropus castanotis*). By F. G. PARSONS, F.L.S., Lecturer on Human and Comparative Anatomy at St. Thomas's Hospital, late Hunterian Professor at the Royal College of Surgeons of England.

[Read 5th March, 1903.]

(With 10 Figures in the Text.)

THE specimen from which the following notes were made was kindly lent me by Prof. Elliot Smith. So far as I can find out little has been hitherto recorded about this animal's anatomy. The skeleton is to be prepared for the Cambridge Zoological Museum, so I have devoted my attention to the soft parts.

JOINTS.

The shoulder-joint has a well-marked gleno-humeral ligament in the anterior part of its capsule; this band runs from the dorsal side of the attachment of the biceps downward and outward to the front of the lesser tuberosity of the humerus.

In the elbow the head of the radius lies antero-externally to the articular surface of the ulna, it is a circular disc as in Man, and pronation through about a quarter of a circle is possible; the orbicular ligament, however, is only feebly marked.

In the wrist-joint the ulna hardly takes any part, the articulation is between the radius above and the scaphoid, semilunar, and cuneiform below, but there is a slight joint-cavity completely shut off from the rest between the ulna and the pisiform.

In the hip the ligamentum teres is well marked.

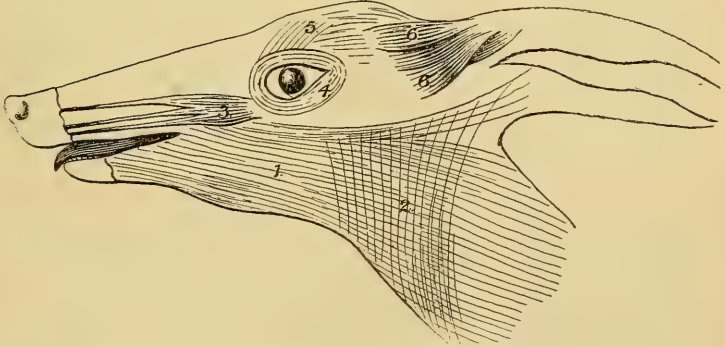
The knee is like that of most other mammals, the posterior attachment of the external semilunar cartilage is to the intercondylar notch of the femur, while the head of the fibula shows none of the freedom of movement so characteristic of many other marsupials*. In this typical mammalian knee *Chæropus* agrees with *Perameles* and differs from many other marsupials.

The internal lateral ligament of the ankle consists of tibio-navicular and tibio-astragular bundles, while on the outer side the middle and posterior fasciculi of the external lateral ligament are present. As the tibia and fibula become synostosed in the lower half of the leg, there is no inferior tibio-fibular articulation.

THE MUSCLES.

Panniculus carnosus.—This is well developed and has the typical mammalian arrangement †. The abdomino-humeral part

Fig. 1.



1. Platysma. 2. Sphincter colli. 3. Retractor naris. 4. Orbicularis palpebrarum. 5. Frontalis. 6. Anterior auricular muscles.

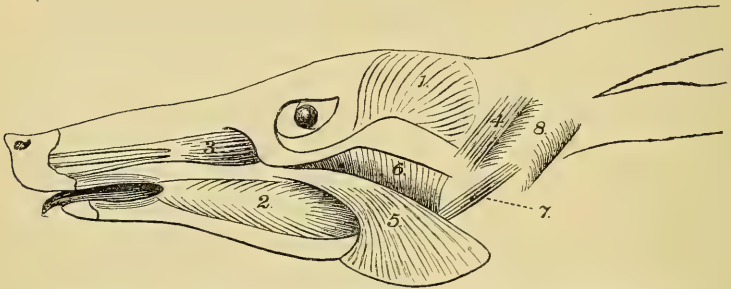
is very well developed and, as usual, divides to enclose the pectoralis, but the part which passes superficial to that muscle

* "Joints of Mammals," Journ. of Anat. vol. xxxiv. p. 312.

† "Muscles of Mammals," Journ. of Anat. vol. xxxii. p. 428.

is specially well developed. The achselbogen passing from the coraso-humeralis across the axilla are well marked. Deep to the platysma is a very definite sphincter colli, which, however, does not reach back so far as the sternum. The facial muscles are simple, and consist of a retractor naris rising below and in front of the orbit and dividing into several fine tendons, orbicularis oris and palpebrarum, frontalis, depressor labii inferioris, four anterior auricular muscles and two posterior. The most curious of the facial muscles is one which I have never met with in other mammals; it rises from the root of the zygoma and

Fig. 2.



1. Temporal. 2. Buccinator. 3. Retractor naris. 4. Deep Parotido-auricularis. 5. Superficial Masseter. 6. Deep Masseter. 7. Third part of Masseter. 8. Auditory Meatus.

passes upward and backward, deep to the parotid, to be inserted into the commencement of the helix. I would suggest the name of deep parotido-auricularis for it. There is no distinct zygomaticus or levator labii superioris.

Muscles of Mastication.

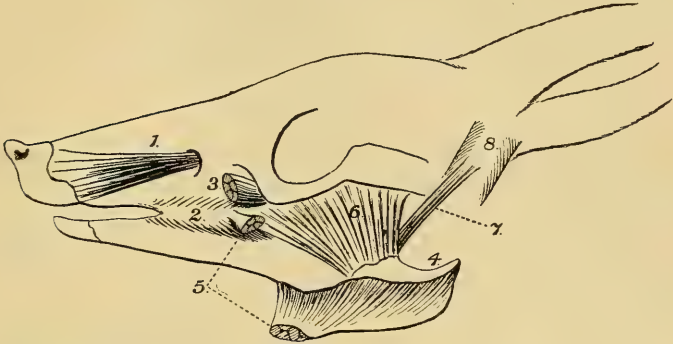
The *Temporal* does not meet its fellow in the mid-line of the skull, it is divided into two very distinct planes.

The *Masseter* also has the two planes very clearly separated: the superficial rises by a narrow tendon from the malar, and spreads out in a fan-like way to be inserted into the lower margin of the mandible as far back as the tip of the angular process; the deep plane is also fan-shaped, but is inverted, the broad part rising from the whole length of the zygoma, while the insertion converges to the outer surface of the ramus of the jaw.

A third slip of the masseter which I have never found in other mammals rises from the cartilage of the external

auditory meatus and runs obliquely downward and forward, as a narrow band, to be inserted into the outer surface of the ramus of the mandible deep to the portion of the masseter last described.

Fig. 3.

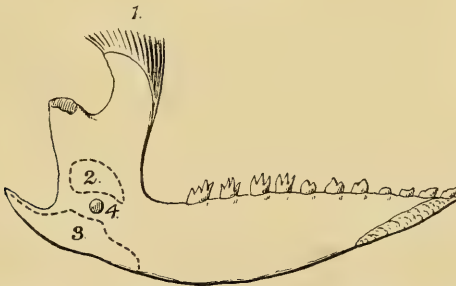

1. Infraorbital Nerve. 2. Buccinator. 3. Retractor naris (cut). 4. Angle of Mandible. 5. Superficial Masseter (cut). 6. Deep Masseter. 7. Third part of Masseter. 8. Auditory Meatus.

I think it is supplied by the third division of the fifth, but on this point I am not quite certain as the nerve was so extremely small.

The *Pterygoids* are remarkable for the lowness of their insertions: the externus, instead of passing to the condyle, is attached to the inner surface of the ramus just above the inferior

Fig. 4.



1. Temporal. 2. External Pterygoid. 3. Internal Pterygoid.
4. Inferior dental foramen.

dental foramen, which is also singularly low down; while the internus is inserted into the lower border of the mandible, which, as in all marsupials, is incurved. It is worth while considering

whether the characteristic inflection of the angle of the marsupial mandible may be due to the concentration of the pull of this internal pterygoid on the lower margin of the jaw.

The *Digastric* runs from the paroccipital process to the middle third of the mandible; it has the usual double nerve-supply and its central tendon, although very short, is distinct.

I noticed nothing special about the *Buccinator*.

Styloid Muscles.

No *Stylo-hyoid* was found.

The *Stylo-glossus* is large and distinct.

The *Stylo-pharyngeus* is also well marked, and has the glosso-pharyngeal nerve winding round its posterior border as in Man and other mammals.

Other Neck Muscles.

The *Sterno-mastoid* is a single muscle on each side, rising from the anterior (cephalic) border of the manubrium and being inserted into the paramastoid process; the spinal accessory nerve passes deep to it, and no representative of a cleido-mastoid was seen.

The *Omo-hyoid* is present; there is no sign of a central tendon or intersection.

The *Omo-trachelian* passes from the transverse process of the atlas to the tip of the acromion under cover of the trapezius.

Muscles joining the Shoulder to the Trunk.

Pectoralis.—This consists of three layers: α , the most superficial, rises from the manubrium and is inserted into the lower half of the humerus; β rises from the whole length of the sternum and is inserted into the middle third of the humerus; γ , the deepest part, rises from the linea alba for a short distance behind (caudal to) the xiphisternum, and passes deep to the other parts to be inserted into the humerus just below the lesser tuberosity. α and apparently a small part of β are supplied by the external anterior thoracic, while γ and the rest of β are supplied by the great internal anterior thoracic, which also supplies the greater part of the panniculus.

The *Cephalo-humeralis* rises from the occipital curved line and is inserted into the middle third of the humerus. If the cleido-occipital part of the sterno-mastoid is present it is entirely fused with this muscle.

The *Trapezius* rises by one continuous origin from the occipital crest, ligamentum nuchæ, and thoracic spines as far as the 11th; it is inserted partly into the cephalo-humeral, partly into the acromial process and spine of the scapula.

The *Rhomboid* also forms one continuous sheet rising from the occipital crest, ligamentum nuchæ, and anterior 6 thoracic spines; it is inserted into the vertebral border of the scapula.

The *Latissimus dorsi* rises from the 11th, 12th, and 13th ribs, the posterior 4 or 5 thoracic spines, and the lumbar fascia; it has the usual insertion into the surgical neck of the humerus.

The *Latissimo-olecranalis* (dorso-epitrochlearis) rises as usual from the latissimus dorsi and is inserted into the inner side of the olecranon.

The *Sterno-scapularis* rises from the manubrium close to the first rib and passes to the fascia over the supraspinatus; there is not even a fibrous intersection to mark the position of the clavicle.

Muscles of the Arm.

Deltoid.—The clavicular fibres, of course, form part of the cephalo-humeral. The acromial fibres are very scanty and, contrary to the rule in mammals, are inserted higher than those coming from the spine. The spinous portion is well developed, and is inserted about the junction of the upper and middle thirds of the humerus.

The *Scapular Muscles* show nothing of special interest. (The levator anguli scapulæ and serratus magnus are included with the trunk-muscles.)

The *Teres major* rises from the third of the axillary border nearest the angle, its insertion is entirely dorsal to that of the latissimus dorsi.

The *Teres minor* is very small and rises from the third of the axillary border nearest the glenoid cavity.

The *Coraco-brachialis* is entirely absent.

The *Biceps* has only the long head, which passes as usual through the capsule of the shoulder-joint.

The *Brachialis anticus* has only the long head, which rises from the back of the surgical neck of the humerus; it is entirely supplied by the musculo-cutaneous nerve. Owing to the necessity for preserving the skeleton for mounting, I am not quite certain as to the insertions of the last two muscles, but the biceps seemed to go entirely to the radius.

The *Trieps* has the usual three heads; of these the long and external unite, while the internal remains distinct to the insertion.

The *Pronator radii teres* is inserted into the junction of the upper third with the lower two-thirds of the radius, and at this point the bone suddenly curves.

The *Flexor carpi radialis* is inserted into the base of the radial metacarpal bone (metacarpal of medius).

The *Palmaris longus* is absent.

The *Flexor sublimis digitorum* rises from the internal condyle and splits into two for the two digits (medius and annularis). The tendons are perforated as usual, but the ring noticed in Rodentia, Insectivora, and Carnivora was not seen*.

The *Flexor carpi ulnaris* is absent—a fact which interests me, as I do not remember a similar occurrence in any other mammal.

The *Flexor profundus digitorum* has three distinct heads—one from the internal condyle, one from the olecranon, and one from the upper third of the radius and ulna.

The general morphology of this muscle in mammals will be found in the reference just given, and it seems to me that the head from the condyle is the radio-condylar; that from the olecranon is the ulno-condylar which has slipped down, although it is true that when this slips down in the Primates it is the coronoid instead of the olecranon which it goes to; while the head from the radius and ulna is the fused radial and ulnar heads.

Only one *Lumbrical* is present, and that comes from the tendon to the annularis.

The *Pronator quadratus* is attached to the lower third of the radius and ulna.

The *Epitrochleo-anconeus* is absent.

The *Anconeus* is remarkable for having a broader attachment to the humerus than to the ulna.

There is only one *Extensor carpi radialis*, and this passes from the external supracondylar ridge to the base of the metacarpal bone of the medius; it therefore probably is *extensor carpi radialis breviar*.

The *Extensor communis digitorum*, like the flexor sublimis and profundus, gives off two tendons to the medius and annularis.

The *Extensor minimi digiti* is a distinct muscle rising from

* "Muscles of Mammals," Journ. of Anat. vol. xxxii. p. 731.

the external condyle and joining the tendon of insertion of the extensor communis to the annularis.

The *Extensor carpi ulnaris*, unlike its corresponding flexor, is well developed and is inserted into the base of the rudimentary metacarpal bone of the fifth digit (minimus).

The *Supinator brevis* passes as usual from the external condyle to the upper fourth of the radius; it has only one layer, deep to which the posterior interosseous nerve passes, and no sesamoid bone is developed in its tendon.

The deep extensors are represented by only one muscle, which rises from the extensor surface of the ulna and joins the extensor communis tendon to the medius; its large origin is like that of the extensor ossis metacarpi pollicis, while its insertion is that of the extensor profundus, of which the extensor indicis is the only remnant in Man. Probably both these elements have been fused into the single muscle found in *Chæropus*.

The *Muscles of the Palm* are very simple and consist of two double-headed flexores breves, one for the medius, the other for the annularis. Dorsal to these there is absolutely no muscle at all, neither are there any adductors superficial to them.

Muscles of the Trunk.

The *Rectus abdominis* runs from the pubis to the first rib; no lineæ transversæ could be made out in it, although they were carefully looked for.

The *Pyramidalis* is not well marked; it rises from the inner side of the marsupial bone and is inserted into the linea alba about one third of the way from the pubis to the xiphisternum.

The *External oblique* rises from the fifth to the thirteenth rib; five lineæ transversæ were seen in it.

The *Supracostalis* is present, though small; it rises from the junction of the second rib with the sternum and runs outward and forward to be inserted into the first rib.

The *Internal oblique* and *Transversalis* are inseparable; they both help to form the cremaster which runs down on the cord, being specially strong on its outer side, and spreads out to form a well-marked muscular bag for the testis, so that each testis lies in a separate muscular bag.

The *Serratus magnus* and *Levator anguli scapulæ* (*Serratus ventralis*) as usual form one muscular sheet which rises from the lower four cervical vertebræ and from the first eight ribs.

The *Scalenus ventralis (anticus)* is absent.

The *Scalenus longus* rises from the 3rd, 4th, 5th, and 6th cervical transverse processes and is inserted into the first four ribs.

The *Scalenus brevis* is dorsal to the last, it rises from the 6th cervical vertebra and is inserted into the first rib.

Muscles of the Hind Limb.

As in most of the Mammalia, the sartorius, ectogluteus, caudo-femoralis, and biceps form one sheet; the only special point being that between the sartorius and the ectogluteus there is no distinct tensor fasciæ femoris, unless the muscle which I here call ectogluteus is really tensor fasciæ femoris.

The *Sartorius* runs from the iliac crest to the inner side of the patella. I satisfied myself that it was supplied by the superior gluteal nerve, a point of some little interest when the myology of other mammals is considered.

The *Ectogluteus* passes from the anterior caudal vertebræ and sacrum, and is inserted chiefly into the fascia of the thigh, but slightly into the third trochanter of the femur.

The *Caudo-femoralis (Agitator caudæ)* continues the origin of the last muscle back along the caudal vertebræ, and is inserted by a narrow tendon into the outer side of the top of the patella; in the buttock it is much thicker and more bulky than the ectogluteus.

The *Biceps (Flexor cruris lateralis)* is a one-headed muscle rising from the tuber ischii; it is inserted entirely into the fascia of the leg from the knee halfway down.

The *Mesogluteus (Gluteus medius)* rises from the iliac crest and sacrum, and is inserted into the outer side of the great trochanter and somewhat below.

The *Entogluteus (G. minimus)* runs from the dorsal part of the gluteal surface of the ilium to the top of the great trochanter.

The *Gluteus ventralis (G. quartus-scansorius)* rises from the ventral part of the gluteal surface of the ilium, and is inserted into the front of the great trochanter.

All the above-mentioned muscles, with the exception of the biceps, are supplied by the superior gluteal nerve, which emerges from the sciatic notch anterior to (cephalad) the pyriformis. The biceps, however, is supplied by the nerve to the hamstrings which comes out of the notch behind (caudad) the pyriformis.

The *Pectineus* is single and small.

The *Adductor Mass* is with difficulty separable into two planes: the more anterior is adductor longus and is inserted into the middle third of the femur; the rest comprises the brevis and magnus and is attached to the lower half of the femur.

The *Gracilis* is single and has the usual attachments; below it is slightly connected with the semitendinosus.

In the *Quadriceps extensor cruris* there is absolutely no reflected head to the rectus femoris, while the vastus externus is, as usual, larger than the internus.

The *Short Rotators of the Hip* show nothing of special interest.

The *Semitendinosus* rises from the anterior caudal vertebræ and the tuber ischii; in the lower part of the thigh it divides into two parts, the larger of which has the usual insertion into the inner side of the top of the shaft of the tibia, while the smaller slip joins the insertion of the biceps on the outer side of the leg. From the insertion of the internal, larger part of the muscle, a tendinous cord runs down along the inner side of the tendo Achillis to be inserted into the tuber calcis.

The *Semimembranosus* and *Presemimembranosus* are closely connected in their whole extent; they rise from the tuber ischii, and in the lower part of the thigh the presemimembranosus is inserted into the lower fourth of the back of the femur, while the semimembranosus passes as usual to the inner side of the head of the tibia deep to the internal lateral ligament. It is interesting to notice that between the presemimembranosus and the adductor mass there is no connection at all.

The *Tibialis anticus* rises from the upper fourth of the external surface of the tibia; it has no femoral origin and is inserted into the base of the metatarsals of the rudimentary index and medius toes.

There is no *Extensor proprius hallucis*.

The *Extensor longus digitorum* is peculiar: it rises close to the tibialis anticus from the upper fourth of the outer surface of the tibia and divides into two planes; the more superficial of these sends one long tendon to the middle and distal phalanges of the big annularis toe, while the deep plane sends a similar tendon to the proximal phalanx of the same toe.

The *Extensor brevis digitorum* is reduced to a mere fibrous band which runs from the calcaneum to the extensor tendon.

The *Peroneus longus* rises from the head and upper fourth of the fibula, it runs through a bony tunnel in the sole and is

inserted into the metatarsals of the rudimentary internal toes (index and medius).

The *Peroneus brevis* rises from the fibula in front of the last, and is inserted into the base of the metatarsal bone of the fifth toe (minimus).

The *Peroneus quinti digiti* comes from the second quarter of the fibula and is inserted into the dorsum of the terminal phalanx of the fifth toe. It will be seen that this is the only extensor tendon of the fifth toe.

The two heads of the *Gastrocnemius* rise from just above the condyles; in the origin of the outer one a flabella is developed. The tendons from these two bellies with that of the plantaris are twisted in the rope-like manner so often seen in mammals*, and are inserted as usual into the calcaneum. From the inner side of the tendon just above its insertion a curious oblique band of fibres runs downward and forward to be inserted into the plantar fascia; I have not seen this in any other mammal.

The *Plantaris* is larger in bulk than either head of the gastrocnemius; it rises from the flabella behind the external condyle and its tendon winds round in the usual way from the deep to the superficial aspect of the tendo Achillis. In the sole it forms a tough fibrous sheet which divides for the 2nd, 3rd, and 4th toes, each slip forming a flexor perforatus and being inserted into the middle phalanx.

The *Popliteus* is small and has the usual attachments, it is inserted into the upper eighth of the posterior surface of the tibia.

The *Rotator fibulæ* is so slight as to be almost unrecognizable, it forms a very feeble deep layer of the last muscle; in this animal there is no movement between the tibia and fibula.

The *Flexor tibialis* and *Flexor fibularis* rise from the upper half of the tibia and fibula, their tendons fuse in the sole and eventually form the flexores perforantes for the 2nd, 3rd, and 4th digits (index, medius, and annularis). As in the hand, there is one lumbrical for the annularis digit.

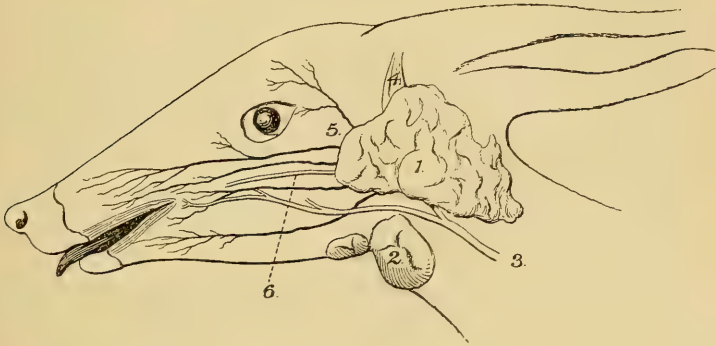The *Sole Muscles* consist only of three flexores breves, which, as usual, are double-headed; one of these is common to the rudimentary index and medius digits, one belongs to the great annularis and one to the minimus; this flexor brevis of the minimus is the only flexor muscle of that digit.

* "Morphology of the Tendo Achillis," Journ. of Anat. xxviii. p. 414.

THE VASCULAR SYSTEM.

The following are some points about the vessels which appeared to me interesting. The aortic arch only gives off two branches, the innominate and the left subclavian; the former after giving off the right subclavian divides into right and left carotids*.

Fig. 5.



1. Parotid gland. 2. Submaxillary gland. 3. External Jugular vein. 4. Deep Parotido-auricularis muscle. 5. Placed just above the transverse facial artery (the other black lines represent the branches of the Facial Nerve). 6. Parotid (Stensen's) duct.

The face is supplied, as in many other long-faced mammals, not by a facial artery coming over the mandible as in Man, but by a branch which comes off from the root of the temporal artery at the termination of the external carotid, and which is represented, I suppose, by the transverse facial artery of Man.

The brachial artery passes through the supracondylar foramen with the median nerve, and then continues down the forearm with that nerve as a median artery until the palm is reached. The aorta terminates in the usual marsupial method, the two external iliacs coming off some distance above the two internal. The femoral artery gives off a large saphenous branch in the lower part of the thigh; this reaches the posterior surface of the tibia and eventually the sole of the foot.

There are two *venæ cavæ*; the post *vena cava* lies ventral to the termination of the abdominal aorta, as is so often the case among marsupials.

* "Arrangement of Branches of Mammalian Aortic Arch," Journ. of Anat. vol. xxxvi. p. 394.

THE NERVOUS SYSTEM.

The *Brachial plexus* is formed by the 5th, 6th, 7th, and 8th cervical and part of the 1st thoracic nerve, its arrangement is singularly like that of Man.

The *Musculo-cutaneous nerve* comes from the 6th and 7th cervical and supplies the biceps brachialis anticus and the skin of the outer side of the forearm.

The *Median nerve* rises by the usual two heads and gets its fibres from the 6th, 7th, 8th cervical and 1st thoracic nerves; it passes through the supracondylar foramen with the brachial artery, supplies all the muscles of the flexor surface of the forearm except the greater part of the flexor profundus digitorum, and then accompanies the median artery to the palm, where it ends by supplying the two digits.

The *Ulnar nerve* comes from the 8th cervical and 1st thoracic; as the minimus digit is suppressed it ends in the flexor profundus digitorum.

The *Internal cutaneous* supplies the inner side of the forearm with cutaneous twigs.

The *Internal anterior thoracic* is, as usual in the lower mammals, very large; it supplies all the ventral part of the panniculus, and apparently some at least of the dorsal part, as well as a great deal of the pectoral mass. The more cephalic part of this mass is supplied by the *external anterior thoracic* from the 6th and 7th cervical.

The *Musculo-spiral nerve* comes from all the nerves forming the plexus except the 5th cervical. After supplying the triceps and the skin of the arm, it divides at the elbow into radial and posterior interosseous, the former of which supplies the dorsal surfaces of the two digits, while the latter passes deep to the supinator brevis and supplies the muscles on the dorsal surface of the forearm, ending, as usual, on the dorsum of the carpus. In the Kangaroo and Phalanger I have found that the area usually supplied by the radial has a branch from the median instead. *Chæropus* shows that this is not a constant occurrence in marsupials.

The *Circumflex nerve* as usual supplies the deltoid, teres minor, and skin over the deltoid. I failed to find any gangliform enlargement on the nerve to the teres minor.

Owing to the necessity of keeping the skeleton intact I was unable to be quite sure of the arrangement of the lumbo-sacral plexus. I shall therefore omit its description.

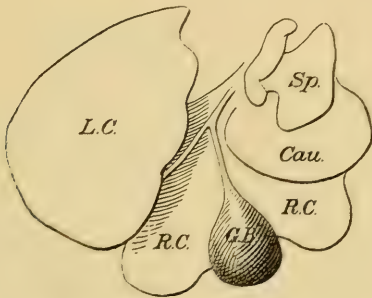
VISCERA.

The *Left Lung* is not divided into lobes.

The *Right Lung* has a well-marked azygos lobe and a slight fissure near the ventral margin. There is an eparterial bronchus on the right side only.

The *Liver* has the same four lobes that are found in Man, if the quadrate is not counted as a primary lobe; but it will be

Fig. 6.



Caudal surface of Liver. L.C. Left central lobe. R.C. Right central lobe.
G.B. Gall-bladder. Cau. Caudate lobe. Sp. Spigelian lobe.

noticed that the gall-bladder divides the right central lobe into two parts, the more median of which would of course correspond to Man's quadrate lobe. The lobe which I have named caudate occupies the usual position of the mammalian caudate lobe, that is to say, it rests upon the right kidney; this is my only reason for regarding it as caudate rather than right lateral. The gall-bladder, it will be noticed, is rather large.

The *Stomach* is remarkable for the great size of the cardiac portion as well as for the attempt at a marking off of a small secondary chamber or pyloric antrum.

The *Small Intestine* is 18 inches from the pylorus to the ileo-cæcal valve; the length of the body from the snout to the root of the tail is 10 inches: the small intestine is therefore $1\frac{4}{5}$ the length of the body.

The *Ileo-cæcal valve* is a flat disc-like protrusion in the cæcum with a puckered orifice, the edges of which are in close apposition.

The *Cæcum* is 4 inches long and is connected by a meso-cæcum with the lower part of the small intestine.

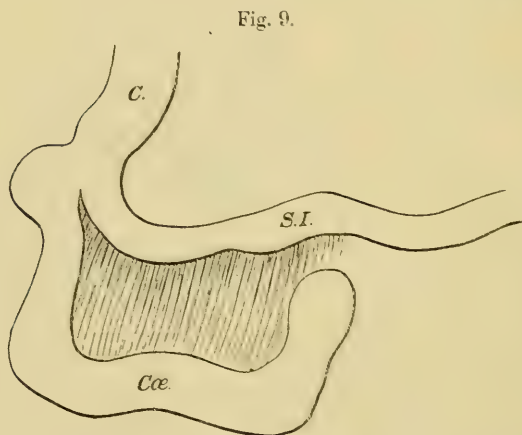
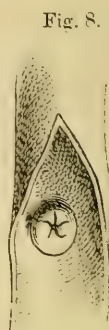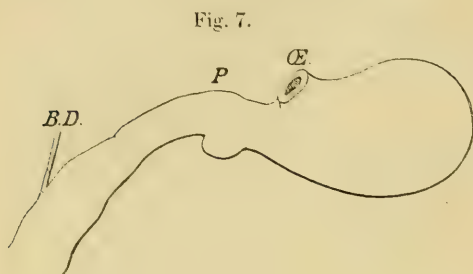


Fig. 7.—Stomach. Æ. Oesophagus. P. Pylorus. B.D. Bile-duct.

Fig. 8.—Cæcum laid open to show Ileo-cæcal valve.

Fig. 9.—C. Colon. Cæ. Cæcum. S.I. Small intestine.

The *Colon* and *Rectum* measure $10\frac{1}{2}$ inches together.

The *Spleen* was entirely absent. I feel quite positive on this point, as I searched for it with the greatest care, and all the viscera were examined immediately after the abdomen was opened, so that it could not have been removed in my absence. I have recently been told that there are one or two recorded cases of absence of the spleen in Mammals, though I have been unable to

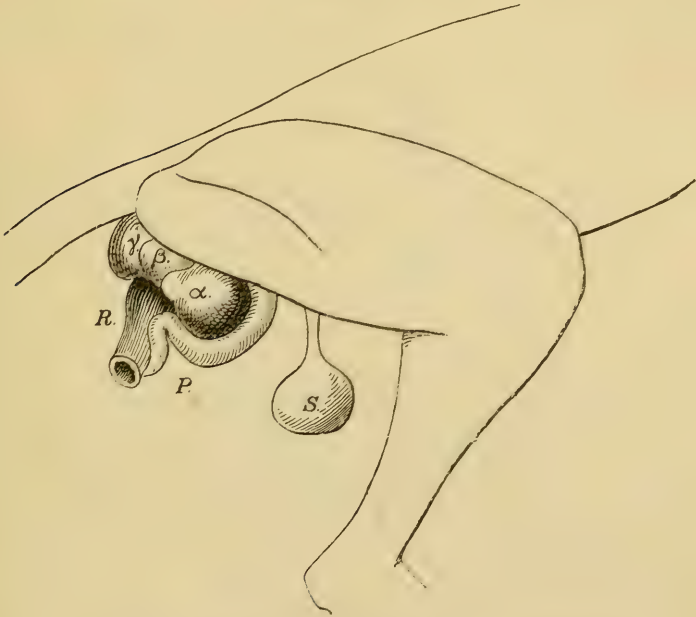
trace the records; and when one considers how very comfortably men and animals live after its removal one wonders that it should not be more often absent. I looked to see whether there were any signs of the spleen having been removed during life, but could find no signs of a scar in the abdominal wall or any traces of ligatured vessels.

The *Kidneys* are in the usual position, the right one $\frac{1}{2}$ inch nearer the head than the left.

The *Adrenals* are separate from the kidneys and near the great vessels, the right one slightly more cephalic than the left.

The *Bladder* is small and somewhat fusiform in shape, while the *Prostate* is very large.

Fig. 10.



a. Corpus spongiosum. β , γ . Cowperian glands. R. Rectum.
P. Penis. S. Scrotum.

The *Testes* are remarkable for their wide separation from the epididymes, and there is a distinct fold of visceral tunica vaginalis running from the one to the other. The globus minor of the epididymis is larger than the globus major.

The *Penis* has an S-shaped curve, and its terminal portion lies

along the ventral wall of the rectum; at the second curve, which forms a sharp kink, two muscular bands or retractors are attached, the other ends of which run to the ventral wall of the rectum. On each side of the rectum are situated four glandular masses of spherical shape. Three of these (α , β , and γ) are shown in the diagram (fig. 10); the fourth one is small and is hidden by the one marked γ . On section γ shows a series of concentric fibrous planes of a pale colour, while the darker soft tissue between is on microscopic examination seen to be glandular. Prof. A. H. Young has referred in detail to these bodies in the Koala (Journ. Anat. & Phys. vol. xiii. p. 316), and he has pointed out that, while three of them are Cowperian glands, the fourth (corresponding to α in fig. 10) is one half of the divided corpus spongiosum. This conclusion a section of α compared with that of γ seemed to bear out, though the specimen had not been well enough preserved for careful microscopic study.

Further Notes on the Lemurs, with especial Reference to the Brain. By G. ELLIOT SMITH, M.D. (Communicated by Prof. G. B. HOWES, D.Sc., LL.D., F.R.S., Sec.L.S.)

[Read 5th March, 1903.]

(With 4 text-figures.)

SINCE my memoir on the Prosimian brain was presented to the Society*, I have come into possession of some valuable material which is of sufficient interest to call for these additional notes. At the same time, I shall avail myself of the opportunity of referring to some interesting communications of Hubrecht † and Earle ‡, with which I was not acquainted when my memoir was written. Professor Howes has called my attention to these, and generously lent me copies of them.

* Trans. Linn. Soc., Ser. II. Zool. vol. viii. pp. 319-432. References in this paper under "Mem." refer to the illustrations of the memoir.

† A. A. W. Hubrecht, "The Descent of the Primates," Princeton Lectures, New York, 1897. (Compare also "Die Keimblase von Tarsius," Festschrift für Carl Gegenbaur, Leipsig, 1896.)

‡ Charles Earle, "The Lemurs as Ancestors of the Apes," 'Natural Science,' vol. x. no. 63, May 1897.

Id., "On the Affinities of *Tarsius*: a Contribution to the Phylogeny of the Primates," The American Naturalist, vol. xxxi. July 1897, pp. 367 *et seq.*